

SUMMARY OF STUDY

Symptoms Prior to Treatment

- Radiating pain into the buttocks and legs
- Burning sensation down both legs into the feet and the right inguinal region.

Activities Making Symptoms Worse

- Walking and standing for more than 15 minutes
- Disrupted sleep
- Difficulty moving from a sitting to a standing position

MRI showed

- Disc protrusions at all lumbar levels
- Degenerative changes throughout lumbar spine
- Decreased Disc Space

7 Week Protocol

- 22 Treatments

Post Treatment

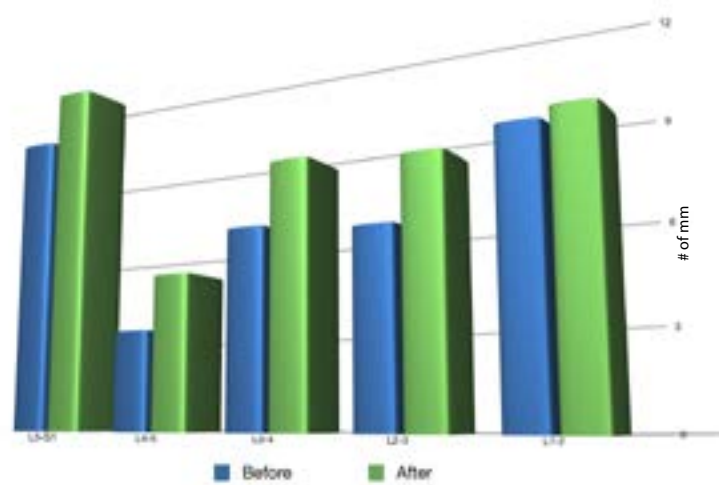
- Pain went from a 10 on a scale of 1-10 down to a 1
- No longer felt the burning sensation in the buttocks or legs
- Decrease in the frequency of burning in the right inguinal region
- Improvement in muscular strength

MRI revealed

- Decreased herniation size
- Increased disc height at multiple lumbar levels



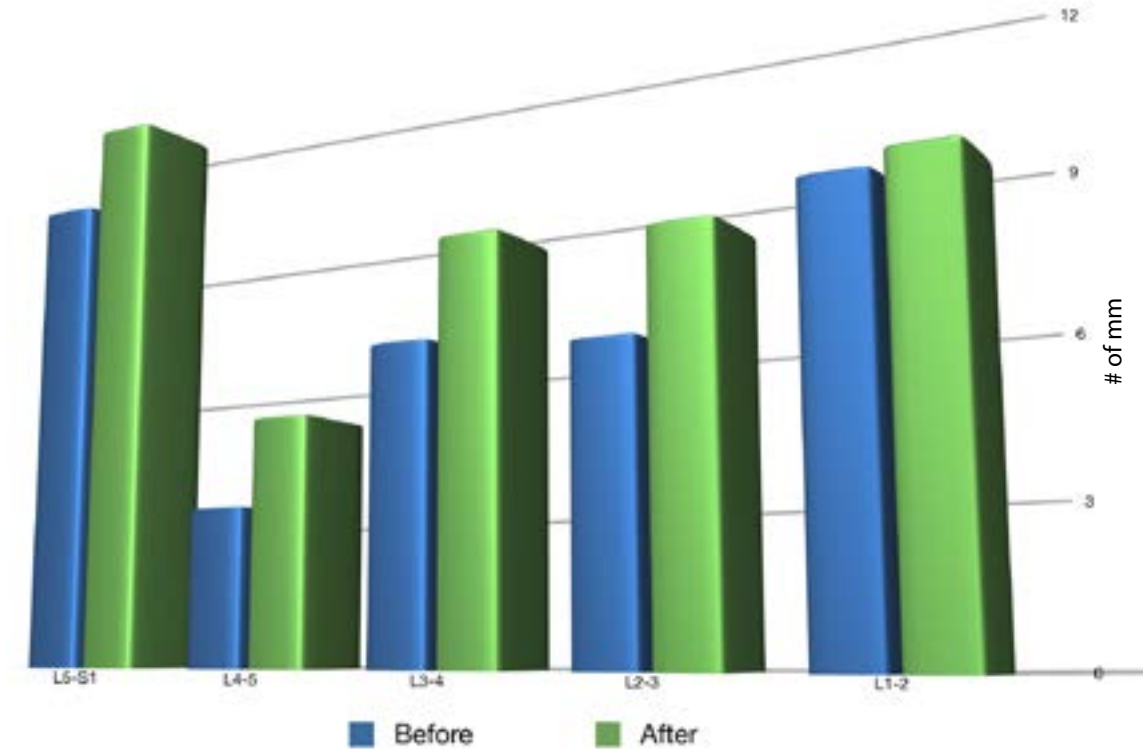
Increase in Disc Height



Research Proves Spinal Decompression Can Lead to an

Increase in Disc Height

And an up to 90% Reduction in Pain



A report by Joseph V Pergolizzi Jr, Adjunct Assistant Professor, Department of Medicine, Johns Hopkins University School of Medicine, Baltimore; Frank Florio, Director of Clinical Research, Axiom Worldwide, Tampa; William R Martin, Medical Director, Upper Valley Interventional Radiology, McAllen; and Charlotte Richmond, Director of Clinical Research, NEMA Research, Inc., Miami Beach.

Individual results may vary. These statements have not been evaluated by the FDA. All spinal decompression devices currently registered with the FDA have received their 510 K clearance by claiming their device is substantially similar to predicate traction devices.

Management of Low-back Pain with a Non-surgical Decompression System (DRX9000™) – Case Report



(480) 626-3766

www.painfreeinaz.com



CASE REPORT: Management of Low-back Pain with a Non-surgical Decompression System (DRX9000™)

CALL TODAY
(480) 626-3766

www.painfreeinaz.com



A report by Joseph V Pergolizzi Jr, Frank Florio, William R Martin, and Charlotte Richmond

Chronic low-back pain (LBP) is a widespread and debilitating syndrome. Approximately 25% of adults in the US report having experienced LBP in the past three months.¹ LBP is the second most common reason for a visit to a physician, the fifth most common cause of admission to a hospital, the third most common indication for surgery,² among the top 10 reasons for visits to internists and the most common and most expensive reason for work disability.³ While there are three broad treatment options for treating LBP – surgical, non-surgical and pharmacological – there is little consensus on which approach is appropriate or preferable for various scenarios. Current evidence-based guidelines recommend conservative treatment for at least two months, and often for much longer, before a surgical option is considered.^{4,5} Surgery is associated with risks, and the outcome in many patients with discogenic back pain is unpredictable. Conservative treatments vary widely and are individualised to the patient. These include exercise, yoga, cognitive behavioural therapy, analgesics, superficial heat therapy, patient education/back school, muscle relaxants, systemic corticosteroids, opioids, spinal manipulation, acupuncture, acupressure and transcutaneous electrical nerve stimulation. More recently, a variety of mechanised and motorised spinal decompression systems have been developed to address the pitfalls of the aforementioned therapies. The first of these was the Vertebral Axial Decompression (VAX-D) system (Vat-Tech, Inc.). Several other devices have since been developed, including the DRX9000™ (Axiom Worldwide, Tampa, Florida). The DRX9000 computerised non-surgical spinal decompression system was designed to provide maximum patient benefits with the use of a non-invasive approach that may help minimise healthcare resources and offer a potentially optimal therapeutic approach to the treatment of LBP.

The DRX9000 aims to relieve pain by enlarging intra-discal spaces, reducing herniation and decreasing intra-discal pressure during treatment. A retrospective chart audit of 94 patients provided preliminary data that chronic LBP may improve with DRX9000 spinal decompression.⁶ A prospective trial with 18 patients found that pain improved significantly after DRX9000 treatment, with patients requiring fewer analgesics and experiencing better function.⁷ Information continues to emerge on non-invasive spinal

decompression. Christian C Apfel and colleagues at the University of California at San Francisco conducted a retrospective review of lumbar computed tomography (CT) scans of 16 patients with chronic musculoskeletal, mechanical or discogenic LBP who underwent a six-week course of non-invasive spinal decompression treatment using the DRX9000. Dr Apfel's investigation showed a significant reduction in chronic LBP after non-invasive spinal decompression correlated with an increase in disc height.⁸ The case report presented here explores the use of the DRX9000 non-surgical spinal decompression protocol for the management of chronic LBP.

Presentation of Case

A 69 year-old man, patient A, presented at an outpatient facility in October 2007. He complained of having experienced LBP during the past year. Patient A said the pain had progressively worsened over the past two months.

Patient A also reported radiating pain into the buttocks and legs, as well as a burning sensation down both legs into the feet and the right inguinal region. Patient A was 68 inches tall and weighed 192 pounds. His medical history revealed cervical spine surgery, diabetes, hypertension and lumbar surgery 13 years previously. Activities that exacerbated patient A's condition included walking and standing for more than 15 minutes. The pain disrupted his sleep and he had difficulty moving from a sitting to a standing position. Magnetic resonance imaging (MRI) of the lumbar spine performed on 4 October 2007 showed disc protrusions at all lumbar levels with degenerative changes throughout; the size of patient A's herniated disc and height of his disc space at first visit are shown in Table 1. Patient A underwent 22 treatments on the DRX9000 over a seven-week period. The initial parameters began at a maximum decompressive force of 80 pounds, with a minimum force of 40 pounds; the final treatment parameters were a maximum of 125 pounds and a minimum of 62 pounds. The decompressive force was raised in increments of five pounds at the discretion of the physician. The angle of treatment force – which allows the physician to make adjustments to treat the affected lumbar region – ranged from 10 to 20°. Adjunctive treatment included electric stimulation, as well as instruction on therapeutic exercise and nutritional support upon discharge. At initial treatment, patient A reported pain at '10' on a scale of 0 to 10; at the end of the treatment protocol

	Size of Herniated Disc (mm)		Height of Disc Space (mm)	
	Pre-Tx MRI	Post-Tx MRI	Pre-Tx MRI	Post-Tx MRI
Date	4 Oct 2007	28 Jan 2008	4 Oct 2007	28 Jan 2008
L5-S1	2.5 (left) 5.1 (centre) 2.5 (right)	2.0 (left) 2.2 (centre) 1.6 (right)	10.2	11.9
L4-5	4.5 (left) 5.1 (centre) 4.8 (right)	3.3 (left) 4.1 (centre) 3.5 (right)	3.3	5.1
L3-4	5.0 (left) 5.9 (centre) 5.2 (right)	3.2 (left) 4.1 (centre) 5.0 (right)	6.4	8.4
L2-3	4.7 (left) 4.6 (centre) 4.8 (right)	3.0 (left) 4.1 (centre) 4.4 (right)	6.1	8.1
L1-2	2.9 (left) 4.0 (centre) 2.7 (right)	- - -	8.6	8.9

Table 1: Pre- and Post-treatment Magnetic Resonance Imaging Measurements for Patient A

he reported pain at '1'. Post-treatment, patient A stated that he no longer felt the burning sensation in the buttocks or legs and noticed a decrease in the frequency of burning in the right inguinal region. At final evaluation the examiner also noted an improvement in patient A's muscular strength and sensation to pinprick. MRI of the lumbar spine performed on 28 January 2008 – four months after the initial visit – revealed decreased herniation size and increased disc height at multiple lumbar levels (see Table 1 for patient A's pre- and post-treatment MRI measurements, and Figure 1 for pre- and post-treatment MRIs of patient A's lumbar spine).

Discussion

Spinal decompression systems such as the DRX9000 have become more prominent in clinical practice for the treatment of LBP. These systems were developed to provide a non-invasive intervention for the treatment of LBP of discogenic origin, with the goal of expanding the intervertebral space and reducing disc protrusion. As described by Richmond et al. in 2007, "the DRX9000 True Non-surgical Spinal Decompression System™ applies spinal distraction forces by using a sensitive computerised feedback mechanism to provide relief of LBP and symptoms associated with herniated discs, bulging or protruding inter-vertebral discs, degenerative disc disease, posterior facet syndrome and sciatica. The DRX9000 uses a split-table design to reduce friction between the patient and the device. The patient lays supine; a chest and shoulder support system controls the upper body and a knee rest is used to eliminate pel-

vic rotation. The apparatus has built-in air bladders, disc-angle-pull adjusters and harnesses and can increase the decompression force more slowly in the latter part of the therapy. The DRX9000 uses a motor pulley to deliver mechanised segmental distraction, which can be delivered in a static or an oscillatory fashion for a pre-selected duration. The location of lumbar spinal disease determines the best pull-angle settings."⁹

A recent review of clinical trials evaluating spinal decompression systems concluded that currently available data are too limited to determine whether spinal decompression provides greater benefit over other non-surgical treatments.¹⁰ Since that review, two new studies have demonstrated the safety and efficacy of the DRX9000.^{6,7} The first study was retrospective and analysed the treatment of 94 patients.⁶ At presentation, patients reported a mean pain rating of 6.05 on a scale of 0 to 10; this decreased significantly to 0.89 at the end of treatment. Analgesic use and physical function were also improved at the end of treatment. No adverse events were noted. The authors acknowledged that the clinical outcomes noted in the study necessitate further investigation.

The second study was a prospective, multicentre, non-randomised phase II pilot study to evaluate the effectiveness and safety of the DRX9000.⁷ Eighteen evaluable study participants underwent a protocol of 20 DRX9000 treatments over the course of six weeks, with five sessions per week in the first two weeks tapering to two sessions per week in the last two weeks. Two patients were removed from the study after the start of treatment because they did not meet the study inclusion criteria. Adjunctive treatment included ice, stretching exercises and analgesics as required. Pain, analgesic use, functionality, patient satisfaction and safety were evaluated throughout the study. Average daily LBP scores decreased from 6.4 to 3.1 after two weeks of treatment and continued to decrease to 0.8 at completion. This represents a >50% reduction in pain after two weeks of DRX9000 treatment. Sixteen patients (88.9%) reported better function as measured by activities of daily living. On a satisfaction scale of 0 to 10, patients gave the DRX9000 an average score of 8.1. Adjunctive pain medication use was decreased with treatment and no significant adverse events or safety issues were reported. Diagnostic imaging is currently being utilised to evaluate physical changes within the intervertebral disc after treatment with the DRX9000. The use of imaging findings may be

beneficial for explaining the clinical improvement in pain and function often observed. Preliminary data from a retrospective review of 16 patients with chronic musculoskeletal, mechanical or discogenic LBP who underwent a six-week course of non-invasive spinal decompression using the DRX9000 appeared to reveal a decrease in chronic LBP correlated with an increase in disc height.⁸ A recently published case study of a 33 year-old male with persistent LBP also demonstrated the positive hydrating effect that the DRX9000 has on the intervertebral disc. Post-DRX9000 MRI measurements showed an increase in intradiscal signal on T2-weighted images at L2-3, L3-4, L4-5 and L5-S1.⁹

Conclusions

Evidence-based data that show the promising effects of DRX9000 on the safe and effective treatment of LBP continue to accumulate. This case report further builds on previous findings that have demonstrated improvements in disc morphology after treatment with the DRX9000. Patient A experienced pain relief, protrusion reduction and disc space enlargement with treatment. To further test the effect of DRX9000 on clinical and radiographic measures in patients with chronic LBP, additional prospective clinical studies are needed.

References

1. Deyo RA, Mirza SK, Martin BI, Back pain prevalence and visit rates: estimate from US national surveys, 2002, *Spine*, 2006;31:2724-7.
2. Krishnaney AA, Park J, Benzel EC, Surgical management of neck and low back pain, *Neuro Clin*, 2007;25:507-22.
3. Jarvik JG, Deyo RA, Diagnostic evaluation of low back pain with emphasis on imaging, *Ann Intern Med*, 2002;137:586-97.
4. Chou R, Qaseem A, Snow V, et al., Diagnosis and treatment of low back pain: a joint clinical practice guideline from the American College of Physicians and the American Pain Society, *Ann Intern Med*, 2007;147:478-91.
5. McCamey K, Evans P, Low back pain, *Prim Care*, 2007;3:71-82.
6. Macario A, Richmond C, Auster M, Pergolizzi JV, Treatment of 94 outpatients with chronic discogenic low back pain with the DRX9000: a retrospective chart review, *Pain Pract*, 2008;8:11-17.
7. Leslie J, Richmond C, Macario A, et al., Pilot: Effectiveness and safety of non-surgical spinal decompression, Presented at the 18th Annual Meeting of the American Academy of Pain Management, 27-30 September 2007, Las Vegas, NV.
8. Apfel C, Cakmakkaya S, Martin W, et al., Decreased lower back pain after non-invasive spinal decompression may be due to restored disc height, Presented at the American Conference on Pain Medicine 3rd Annual conference, April 2008.
9. Richmond C, Florio F, Wilhelm JM, Auster M, Magnetic Resonance Imaging Findings after Treatment with a Non-surgical Spinal Decompression System (DRX9000™) – Case Report, *US Musculoskeletal Review*, 2007;50-52.
10. Macario A, Pergolizzi J, Systematic literature review of spinal decompression via motorized traction for chronic discogenic low back pain, *Pain Pract*, 2006;6:171-8.